The Scientific Journal of King Faisal University

Basic and Applied Sciences

Potential for Using EGFR Expression in Rhabdomyosarcoma, Osteosarcoma and Ewing's Sarcoma: Clinicopathological and Prognostic Significance

Hassan Fouad Huwait [1], Hatim Qasim Almaghrabi [2 3], Mariana Fouad Gayyed [4] and Hanan Mohamed Abd Elmoneim [1 4]

[1] Department of Pathology, Faculty of Medicine, Umm Al-Qura University, Makkah, Saudi Arabia
[2] Department of Pathology and Laboratory Medicine, King Abdulaziz Medical City, King Saud bin Abdulaziz University for Health Science, Jeddah, Saudi Arabia
[3] King Abdullah International Research Center, Jeddah, Saudi Arabia
[4] Department of Pathology, Faculty of Medicine, Minia University, Minia, Egypt

LINK	RECEIVED	ACCEPTED	PUBLISHED ONLINE	ASSIGNED TO AN ISSUE
https://doi.org/10.37575/b/med/220003	19/01/2022	07/04/2022	07/04/2022	01/06/2022
NO. OF WORDS	**NO. OF PAGES**	**YEAR**	**VOLUME**	**ISSUE**
4277	5	2022	23	1

ABSTRACT

Sarcomas are a heterogeneous group of malignant tumors that arise from mesenchymal cells and can arise anywhere in the body, whether it is soft tissue or bone. Epidermal growth factor receptor (EGFR) expression in pediatric sarcomas is explored in the current study. A key feature of EGFRs is their general involvement in signal transduction and oncogenesis, making them one of the most studied receptor protein-tyrosine kinase families. The study included 104 archived formalin-fixed paraffin-embedded blocks assessed using immunohistochemical stains for EGFR expression in rhabdomyosarcoma, osteosarcoma, and Ewing's sarcoma. EGFR gene copy number was analyzed by dual silver in situ hybridization (DISH). EGFR was positively expressed in 56.7% of pediatric sarcoma. Immunostaining for EGFR was significantly associated with deep large tumors, stage, and histologic grade. Significantly, lower chances of overall survival were observed with elevated levels of EGFR five years post-diagnosis. EGFR staining identified independent risk factors for poor patient outcomes. The results of in situ hybridization did not indicate EGFR gene amplification in any of the cases assessed. EGFR overexpression was an independent predictor of pediatric sarcoma outcome, which is highly associated with histologic grade and stage. Results indicate EGFR inhibitors should be potentiated and directed against pediatric sarcoma.

KEYWORDS

EGFR, Ewing's sarcoma, osteosarcoma, rhabdomyosarcoma

CITATION

Huwait, H.F., Almaghrabi, H.Q., Gayyed, M.F. and Abd Elmoneim, H.M. (2022). Potential for using EGFR expression in rhabdomyosarcoma, osteosarcoma and Ewing's sarcoma: Clinicopathological and prognostic significance. *The Scientific Journal of King Faisal University: Basic and Applied Sciences*, **23**(1), 75–9.

DOI: 10.37575/b/med/220003

1. Introduction

Sarcomas are a heterogeneous group of malignant tumors that arise from mesenchymal cells and can arise anywhere in the body, whether it is soft tissue or bone. The data collected by the Saudi Cancer Registry concerning bone sarcoma shows lower incidence rates of pediatric sarcomas than those reported worldwide. It has been thought that factors contributing to this are underreporting by hospitals, a smaller population, and a failure to assess local risk factors (Aljuhani *et al.*, 2021). The prevalence of osteosarcoma, Ewing's sarcoma, and rhabdomyosarcoma in patients younger than 18 is a widespread problem in the Middle Eastern, North African, and West Asian regions (Steliarova-Foucher *et al.*, 2017; Basbous *et al.*, 2021).

In the data collected by the Saudi Cancer Registry, there were high mortality rates for rhabdomyosarcoma (RMS) and about 30% of patients died despite improving treatment outcomes. RMS comprises two main subtypes, embryonal rhabdomyosarcoma (ERMS) (approximately 60%) and alveolar rhabdomyosarcoma (ARMS) (approximately 20%). These two subtypes are similar in morphology but completely different in biological characters, and differentiated upon basis of histopathological, immunohistochemical (IHC) and molecular markers (Rudzinski *et al.*, 2021). An accurate diagnosis of RMS is made by evaluating not just morphology, but also by evaluating ancillary studies, including immunohistochemistry, to reflect the underlying nature of the tumor (Rudzinski *et al.*, 2021).

For bone sarcoma in children and adolescents, osteosarcoma (OS) is the most common of diagnosed cases. It has a bimodal incidence, being rare in children less than five years old, then increases its incidence with age with a peak of incidence during childhood, another peak during adolescence, and then it decreases its incidence again in adulthood (Yang *et al.*, 2021).

Ewing's Sarcoma (ES) has a strong pediatric predilection with high mortality and morbidity among children and young adults. It is a frustrating type of sarcoma with poor prognoses in bone and soft tissue. ES is the second most common type of malignant bone tumor in children and adolescents after osteosarcoma (Zöllner *et al.*, 2021).

A key feature of epidermal growth factor receptors (EGFRs) is their general involvement in signal transduction and oncogenesis, making them one of the most studied receptor protein-tyrosine kinase families. The alteration of EGFRs during cancer progression demonstrates their role as an effective oncogenic driver. EGFRs are membrane-bound receptor tyrosine kinase proteins that are frequently overexpressed in many cancers (Roskoski, 2019). Cancer therapeutics have been developed in part by targeting EGFR's kinase activity, namely with small molecules that target the EGFR ATP binding pocket and monoclonal antibodies that target EGFR ligand binding domains (Roskoski, 2019; Thomas and Weihua, 2019; Kaufman *et al.*, 2021). EGFR proteins are highly expressed in soft tissue sarcoma; therefore, analysis of the activity of EGFR signaling in sarcoma is needed for the detection of predictive markers of patient outcome and survival, and to enhance future strategies of targeted therapy (Yang *et al.*, 2017). EGFR amplification is associated with constant membrane staining, however, IHC markers are not reliable predictors of treatment response, but they are important when performing silver-enhanced in situ hybridization analyses (SISH), that is, identifying tumor areas with highest EGFR gene copy number (GCN) (Ålgars *et al.*, 2011).

The main goal of this study is to reevaluate the prognostic and predictive relevance of EGFR relating to clinicopathological parameters and survival rates in pediatric sarcoma. Herein, the expression of EGFR is assessed by immunohistochemical staining in formalin-fixed paraffin-embedded blocks and gene amplification status from primary tumor or metastases for rhabdomyosarcoma, osteosarcoma, and Ewing's sarcoma.

2. Materials and Methods

2.1. Patients:

Archived formalin-fixed paraffin-embedded blocks were obtained from 104 patients with rhabdomyosarcoma, osteosarcoma, or Ewing's sarcoma. Patients were diagnosed and treated between December 2015 and January 2021. Blocks were retrieved from the pathology files of the National Guard Hospital in Jeddah, Saudi Arabia. All archival blocks of patients admitted for first diagnosis, metastatic or recurrent tumors were selected, but archival blocks belonging to patients with incomplete clinical data or missing follow-

Corresponding Author: Hassan Fouad Huwait 00966505503134, hfhuwait@uqu.edu.sa

up data were excluded. Clinical records included age, gender, type of tumor, date of presentation of illness, history of clinical illness, tumor size, tumor localization, treatment regimen, and patients' response rate to treatments at the end of the study. Relevant clinical data reflecting aggressiveness of the disease or clinical and radiological data of the patients during treatment were evaluated during the follow-up period. Patients were categorized into three groups: complete remission, partial remission, or tumor progression. Two pathologists reviewed all Hematoxylin and Eosin (H&E) stained slides from all cases to determine the sarcomas' histological diagnoses and their subtypes according to the World Health Organization classification (Choi and Ro, 2021).

The study protocol was approved by the Institutional Review Board of the Umm Al-Qura University. Data follow-up began at diagnosis and the median follow-up was 60 months post-diagnosis. Overall survival is defined as the time to death post-diagnosis due to disease-related causes.

2.2. Immunohistochemical Analysis of EGFR:

Immunohistochemical (IHC) staining was conducted on formalin-fixed paraffin-embedded blocks. The paraffin-embedded material was cut into 4 μm sections, dewaxed with xylene, and rehydrated with graded ethanol. The sections were then microwave-irradiated in EDTA buffer for antigen retrieval. After endogenous peroxidase inhibition, sections were subjected to the primary antibody overnight at 4°C, and then stained with a streptavidin-biotin-peroxidase kit. Finally, sections were immersed in 3.3′-diaminobenzidine, counterstained, and mounted. In accordance with the manufacturer's instructions contained with the EGFR detection system, immunohistochemical staining of the paraffin block sections for EGFR (EGFR pharm Dx kit, DakoCytomation, Glostrup, Denmark) was performed using the anti-EGFR monoclonal antibody, clone E30 diluted at 1/100. With each run, negative controls were also included without the primary antibody. Breast carcinomas were used as the positive controls for the anti-EGFR antibody.

In the IHC scoring process, tissue control slides were typically compared with scored slides and two pathologists oversaw the procedure; in addition, a highly circumscribed scoring system was used because of its ease of use. To grant validity to any conclusions based on EGFR staining, a modified score was used that incorporated the fact that EGFR is localized to the membrane and not the nucleus or cytoplasm. Scores were based on the intensity of staining combined with the distribution of the staining. The proper immunohistochemical score of a tumor was based on intensity: 0 = no staining; 1+ = weak staining; 2+ = moderate staining; 3+ = strong staining. The percentage of positive cells was also recorded to impart the diffuse or focal nature of positive cells: sporadic (positive cells < 10%); focal (11% < positive cells < 50%); diffuse (positive cells ≥ 50%). Slides with immunohistochemical scores of 2+ and 3+ with focal to diffuse distribution were considered as positive for EGFR. The location of the EGFR-positive staining was noted as membranous and cytoplasmic (Sato *et al.*, 2005; Salgado *et al.*, 2020).

2.3. Dual Silver-Enhanced In Situ Hybridization (DISH):

On parallel sections of a thickness of 5 μm, the EGFR gene was detected with the Ventana/Roche DNA Probe (EGFR gene) and the Chromosome 7 gene was detected with the Ventana/Roche oligonucleotide Probe (Chr-7 gene). DISH was performed by using the ultra-view SISH Detection Kit (Ventana/Roche). In the area of highest immunohistochemical reactivity from each tumor, Gene Copy Number (GCN) was measured, and Chr-7 numbers (the number of chromosome copies per cell) were counted. The EGFR gene (or centromere 7) was visualized as a single black dot in the nucleus after the silver precipitation was deposited. On the EGFR SISH slides, 20 nuclei from three areas were counterstained, creating a total of 60 nuclei to be analyzed. The copy number ratio of EGFR:Chr-7 was also calculated, in addition to EGFR/Chr-7 averages. The presence of nuclei with a EGFR:Chr-7 ratio of >2 was considered an intensified sample of EGFR (Gaiser *et al.*, 2009).

2.4. Statistical Methods:

Data analysis was performed using Statistical Package for the Social Science (SPSS: An IBM Company, Version 21.0, IBM Corporation, Armonk, NY, USA). The chi-square test was used to evaluate the association between EGFR expression and clinicopathological variables. To estimate the rate ratios for possible factors associated with adverse events, a Cox proportional-hazards regression analysis with forward selection of variables was used. For evaluating the association between overexpression of EGFR and overall survival, Kaplan-Meier plots and log-rank tests were applied. P values ≤ 0.05 were regarded as significant.

3. Results

Clinical and pathological characteristics were compiled from medical records. Table 1 summarizes the clinical and pathological characteristics of the 104 patients in this study. At the time of analysis, all patients had a median follow-up period of 60 months (95% confidence interval). The study group included 38 cases of rhabdomyosarcoma, 35 cases of osteosarcoma and 31 cases of Ewing's sarcoma.

Table 1: Patients Characteristics

Clinicopathological Characteristics		No.	%
Histopathological type	Ewing's sarcoma	31	(29.8%)
	Osteosarcoma	35	(33.7%)
	Rhabdomyosarcoma	38	(36.5%)
Gender	Male	68	(65.4%)
	Female	36	(34.6%)
Age	0–10	34	(32.7%)
	10–19	70	(67.3%)
Site	Trunk	57	(54.8%)
	Extremities	47	(45.2%)
Size	≤ 5 cm	29	(27.9%)
	> 5 cm	75	(72.1%)
Depth	Superficial	41	(39.4%)
	Deep	63	(60.6%)
Grade	Grade 1	22	(21.2%)
	Grade 2	25	(24.0%)
	Grade 3	57	(54.8%)
Stage	Stage 1	24	(23.1%)
	Stage 2	27	(26.0%)
	Stage 3	53	(51.0%)
Vascular invasion	Absent	73	(70.2%)
	Present	31	(29.8%)
Metastasis	Absent	71	(68.3%)
	Present	33	(31.7%)
5 Year Survival	Survival	76	(73.1%)
	Death	28	(26.9%)
Recurrence	Absent	59	(56.7%)
	Present	45	(43.3%)
EGFR	Negative	45	(43.3%)
	Positive	59	(56.7%)

The age range was 0–19 years old showing a median age of 15 at the time of diagnosis, with a striking predominance of males (M:F = 17:9). The primary tumor location was axial in 57 cases (54.8%); the remaining 47 patients (45.2%) had tumors localized in the extremities. Seventy-one patients (68.3%) had the disease locally advanced at the time of diagnosis. The patient characteristics are shown in Table 1.

3.1. Relationships of EGFR Expressions with Clinicopathological Features:

Regarding EGFR-immunostaining, positive cytoplasmic and membranous expression was observed in 59 of 104 (56.7%) patients, which included 17 of 31 (89%) cases of Ewing's sarcoma, 22 of 38 (57.9%) cases of rhabdomyosarcoma and 20 of 35 (57.1%) cases of

osteosarcomas. Representative examples of immunohistochemistry staining for EGFR can be seen in Figures 1–3.

Figure 1: Immunohistochemical pattern of EGFR expression in rhabdomyosarcoma showing strong membranous and diffuse staining. (Magnification X 400).

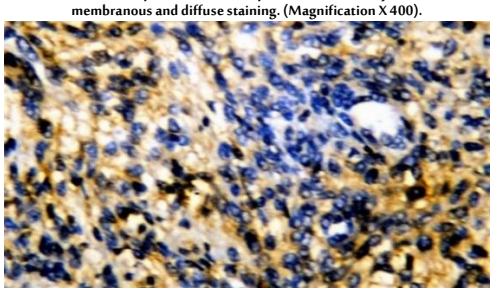

Figure 2: Immunohistochemical pattern of EGFR expression in osteosarcoma showing moderate membranous and diffuse staining. (Magnification X 400).

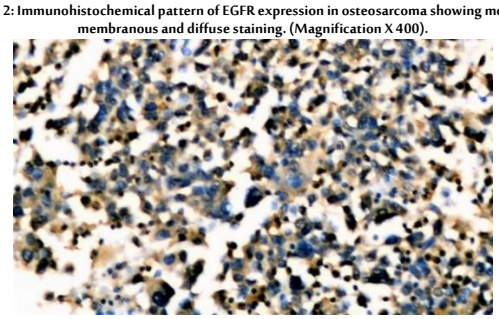

Figure 3: Immunohistochemical pattern of EGFR expression in Ewing's sarcoma showing moderate membranous and diffuse staining. (Magnification X 400).

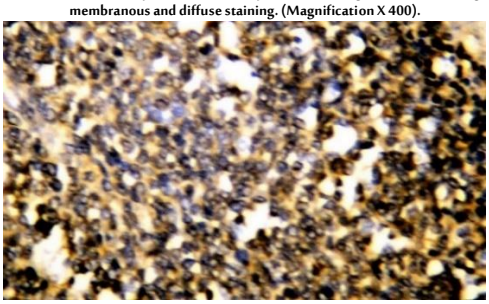

There was a higher frequency of positive immunostaining for EGFR in deeper (P < 0.001) and larger tumors (P = 0.002). Overexpression of EGFR was significantly correlated with tumor stage and histological grade (*P* < 0.001). Age, gender, and anatomic location were not significantly associated with EGFR-positivity. In 104 patients, high levels of EGFR were significantly associated with a lower five-year survival rate. Correlation of the IHC expression of EGFR was performed with different clinicopathological features, as shown in Table 2.

Table 2: Correlation between EGFR and different clinical and pathological factors of pediatric sarcoma

Clinicopathological Characteristics		EGFR		
		Negative	Positive	P value
Type	Ewing's sarcoma	14 (45.2%)	17 (54.8%)	0.966
	Osteosarcoma	15 (42.9%)	20 (57.1%)	
	Rhabdomyosarcoma	16 (42.1%)	22 (57.9%)	
Gender	Male	30 (44.1%)	38 (55.9%)	0.488
	Female	15 (41.7%)	21 (58.3%)	
Age	0–10	18 (52.9%)	16 (47.1%)	0.207
	10–19	27 (38.6%)	43 (61.4%)	
Site	Trunk	23 (40.4%)	34 (59.6%)	0.554
	Extremities	22 (46.8%)	25 (53.2%)	
Size	≤ 5 cm	20 (69.0%)	9 (31.0%)	**0.002**
	> 5 cm	25 (33.3%)	50 (66.7%)	
Depth	Superficial	31 (75.6%)	10 (24.4%)	**0.000**
	Deep	14 (22.2%)	49 (77.8%)	
Grade	Grade 1	17 (77.3%)	5 (22.7%)	**0.001**
	Grade 2	10 (40.0%)	15 (60.0%)	
	Grade 3	18 (31.6%)	39 (68.4%)	
Stage	Stage 1	15 (62.5%)	9 (37.5%)	**0.002**
	Stage 2	15 (55.6%)	12 (44.4%)	
	Stage 3	15 (28.3%)	38 (71.7%)	
Vascular invasion	Absent	37 (50.7%)	36 (49.3%)	**0.030**
	Present	8 (25.8%)	23 (74.2%)	
Metastasis	Absent	37 (52.1%)	34 (47.9%)	**0.010**
	Present	8 (24.2%)	25 (75.8%)	
Recurrence	Absent	36 (61.0%)	23 (39.0%)	**0.000**
	Present	9 (20.0%)	36 (80.0%)	
5 Year Survival	Survival	39 (51.3%)	37 (48.7%)	**0.007**
	Death	6 (21.4%)	22 (78.6%)	

In all 59 cases evaluated, there was no evidence of genomic amplification at either of the test loci, as no EGFR gene copy number signal ratio > 2 could be observed, as can be seen in Figure 4.

Figure 4: Dual-color SISH of the EGFR (black signal) and Chr 7 (red signal) in tissues with no EGFR amplification. (Magnification X 650)

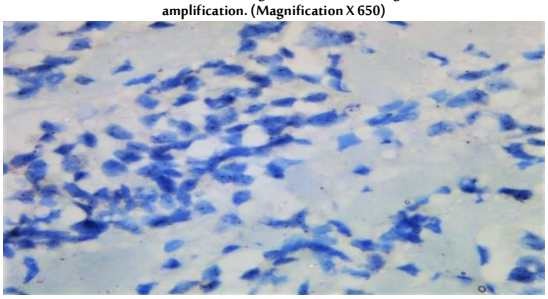

3.2. Survival Analysis:

To examine whether several variables affected survival, univariate analyses showed that tumor stage, histologic grade, depth, metastases, recurrences, vascular invasion, and positive EGFR staining were significant predictors. Based on multivariate analyses, tumor stage, histologic grade, recurrence, and positive EGFR staining were independent risk factors for poor outcomes, as can be seen in Table 3.

Table 3: Univariable and multivariable analysis with respect to five-year disease-free survival in 104 cases of pediatric sarcoma

Clinicopathological Characteristics		Univariable cox model				Multivariable cox model			
		P Value	HR	(95% CI)		P Value	HR	(95% CI)	
				Lower	Upper			Lower	Upper
Gender	Male	0.779	0.893	0.403	1.976				
	Female								
Age	0–10	0.190	1.776	0.752	4.194				
	10–19								
Site	Trunk	0.311	0.675	0.315	1.445				
	Extremities								
Size	≤ 5 cm	0.349	1.539	0.624	3.797				
	> 5 cm								
Depth	Superficial	0.004	5.926	1.788	19.646	0.087	6.772	0.760	60.360
	Deep								
Grade	Grade 1	0.094				0.013	2.166	1.181	3.973
	Grade 2	0.564	1.611	0.319	8.130				
	Grade 3	0.051	3.337	0.997	11.172				
Stage	Stage 1	0.003				0.022	2.475	1.141	5.369
	Stage 2	0.317	2.384	0.436	13.046				
	Stage 3	0.005	8.186	1.916	34.970				
Vascular invasion	Absent	0.000	4.478	2.106	9.523	0.507	1.733	0.342	8.778
	Present								
Metastasis	Absent	0.000	4.508	2.119	9.588	0.386	1.961	0.427	8.998
	Present								
Recurrence	Absent	0.000	0.151	0.061	0.376	0.033	3.217	1.098	9.429
	Present								
EGFR	Positive	**0.012**	3.194	1.289	7.914	0.070	2.438	0.929	6.398
	Negative								

4. Discussion

Rhabdomyosarcoma, Ewing's sarcoma and osteosarcoma account for 34.8% of all childhood cancers (Capasso *et al.*, 2020). Several pediatric sarcomas express the surface proteins with the epidermal growth factor receptor. Although surgical resection is performed and adjuvant therapy is started with early diagnosis of pediatric sarcomas, poor prognoses are expected, so targeted personalized therapies are needed without delay (Pilbeam *et al.*, 2017).

In the current study, high incidence of RMS, ES, and OS occurred during the periods of childhood and adolescence, at a median age of 15 and with male predominance. Rhabdomyosarcoma is most commonly found in male children, who display higher incidence of RMS than females based on the findings of El Demellawy *et al.* (2017). OS and ES also demonstrate these age-related sarcomas during adolescence. An enhanced pubertal growth period may play a role in vulnerability to pediatric sarcoma (Martin-Giacalone *et al.*, 2021).

In this study, there was significant overexpression of EGFR in 59 out of 104 (56.7%) tissue samples of different histologic types. This finding is supported by other studies, suggesting that soft tissue sarcomas are generally over-expressed with EGFR (Yang *et al.*, 2017; Thomas and Weihua, 2019). Osteosarcoma cells exhibit EGFR-signaling, which could be used as a therapeutic target (Ji and He, 2019). Epidermal growth factor may interact with intracellular protein kinase pathways to enhance cell proliferation and

survival and regulate senescence. High EGFR expression is coupled with high proliferation activity and invasion (Pilbeam *et al.*, 2017). In Ewing's sarcoma, inhibition of EGFR changed the cell cycle, prompting arrest in G1 and aggregation of the sub-G1 population. Eventually, polyploidy reduction and accumulation of senescent cells increased (Kersting *et al.*, 2018).

In the current investigation, there was a higher frequency of positive immunostaining for EGFR in deep and larger tumors. This is in contrast with other studies that have concluded that there is no association between EGFR expression and tumor size or site (Sato *et al.*, 2005; Kersting *et al.*, 2006; Yang *et al.*, 2006).

The overexpression of EGFR being significantly correlated with tumor stage and histological grade found in this study agrees with other studies that have concluded that EGFRs are significantly associated with higher histologic grade and clinical stage (Sato *et al.*, 2005; Kersting *et al.*, 2006). The expression of EGFRs and their associated downstream signal transducers was associated with sarcoma progression, suggesting that EGFR downstream signaling pathways may jointly support sarcoma cell survival (Yang *et al.*, 2017). Other authors have revealed the expression of EGFR in 78% of soft tissue sarcoma cases but in those studies the EGFR was not correlated significantly with histological grade and stage (Yang *et al.*, 2006; Teng *et al.*, 2011).

Herein, age, gender, and anatomic location were not significantly associated with EGFR-positivity. These results have also been observed in another report showing no correlation between EGFR expression and metastasis, age, gender, sarcoma histological classification, or anatomic location (Borgatti *et al.*, 2017).

In the present study, increased levels of EGFR were significantly associated with a decreased probability of overall survival at five years post-diagnosis. This suggests that cancer cells expressing the wild type of EGFR aren't dependent on kinase activity but are dependent upon its presence in order to survive, regardless of its tyrosine kinase activity (Thomas and Weihua, 2019). EGFR has historically been associated with poor outcomes in pediatric sarcoma patients treated with EGFR-targeting based on expression in RMS and ES cells (Oh *et al.*, 2018). Expression of the EGFR protein has no association with the tumor-specific patient survival, but low expression of the EGFR protein in conjunction with their RNA analyses were associated with poor patient survival of sarcoma (Rot *et al.*, 2018). The expression of EGFR by tumors typically means a more aggressive type of sarcoma (Braun *et al.*, 2018). Patient gender, location of the primary lesion, and an absence of invasion at diagnosis each had an independent favorable effect on patient survival (Jagodzińska-Mucha *et al.*, 2021). Seventy percent of patients with osteosarcomas and tumors that have spread locally to extremities can survive long-term (Kager *et al.*, 2017).

Based on the multivariate analyses, there were several independent predictors of poor outcomes, including tumor stage, histologic grade, recurrence, and presence of positive EGFR staining. Based on the current data, activated EGFR is an independent predictor for overall survival. In cancer cells, epidermal growth factor and related ligands bind to EGFR and phosphorylate tyrosine kinase residues result in the triggering of other signal transduction pathways. Cancer cells are dependent on mitochondrial metabolism for glucose generation due to their high energetic requirements. These enzymes act in conjunction with the growth factors MAPK, PI3K/Akt, and JAK/STAT, which block cell death (Wang *et al.*, 2020). Inactivation of signaling in several downstream EGFR pathways such as PI3K/AKT and JAK/STAT3 has also been incriminated in osteosarcoma progression and metastasis (Yang *et al.*, 2021).

Anti-EGFR therapies with improved specificity could be selected for patients based on the results of EGFR gene amplification and immunohistochemistry in the treatment of esophageal squamous cell carcinoma and gastric adenocarcinomas (Sunpaweravong *et al.*, 2005; Oyama *et al.*, 2015; Birkman *et al.*, 2016).

All sarcoma tumors in this study group were negative for EGFR amplification using DISH. In a similar study on rhabdomyosarcoma, some cases expressed the EGFR protein, but there was no evidence of chromosome amplification (Ganti *et al.*, 2006). Although this data provides important biological insight, it does not completely rule out the possibility of using EGFR inhibitors with anti-tyrosine kinase activity to treat pediatric sarcoma. Despite the lack of mutations in the EGFR kinase domain in a subset of patients with recurrent malignant glioma, EGFR inhibitors were effective in some cases; PTEN loss and increased signaling through the PI3K-Akt-mTOR pathway were associated with such a response (Nadeem Abbas *et al.*, 2019). It has been recognized that an EGFR mutation is tied to tyrosine kinase inhibitors' reaction in cancer and this reaction is a crucial parameter for cancer patients harboring EGFR mutations (Shi *et al.*, 2018). Using immunohistochemistry, high levels of EGFR in soft tissue undifferentiated round cell sarcomas during infancy were detected, but not accompanied by EGFR amplification, suggesting that protein expression may not be augmented by gene copy number changes (Salgado *et al.*, 2020).

5. Conclusion

A high level of EGFR overexpression in pediatric sarcoma is a significant prognostic factor, independent of the histological grade and stage. The current data concluded a highly frequent EGFR expression and significant association with poor prognostic parameters in pediatric sarcoma. EGFR inhibitors are potential therapeutic agents that can be developed and directed at pediatric sarcomas displaying EGFR protein and gene expression.

Acknowledgements

The authors would like to thank Deanship of Scientific Research at Umm Al-Qura University for the continuous support. This work was supported financially by the Deanship of Scientific Research at Umm Al-Qura University to Dr. Hassan Fouad Huwait [Grant Code: MED-1-01-0002-17].

Funding

The authors disclosed receipt of the following financial support for the research, authorship, and/or publication of this article: This work was supported by Deanship of Scientific Research at Umm Al-Qura University [Project ID: MED-1-01-0002-17].

Biographies

Hassan Fouad Huwait

Department of Pathology, Faculty of Medicine, Umm Al-Qura University, Makkah, Saudi Arabia, 00966505503134, hfhuwait@uqu.edu.sa

Dr. Huwait is a Saudi assistant professor who received his Ph.D. in pathology from the University of British Columbia, Vancouver, Canada. He is a Fellow of the Royal College of Physicians and Surgeons of Canada. He served as Chairman of the Pathology Department at Umm Al-Qura University. He is a surgical pathology consultant at Umm Al-Qura University and National Guard Hospital in Jeddah, Saudi Arabia. He is also an anatomical pathology consultant in the Department of Pathology at Security Force Hospital, Makkah, Saudi Arabia, and in the Department of Pathology at King Abdulaziz Medical City, Jeddah, Saudi Arabia. Hassan has published 21 ISI/Scopus-indexed scientific papers with special research interests in breast, bone, and soft tissue pathology, dermatopathology, and surgical pathology. ORCID: 0000-0002-0336-7639.

Hatim Qasim Almaghrabi

Department of Pathology and Laboratory Medicine, King Abdulaziz Medical City, King Saud bin Abdulaziz University for Health Science, Jeddah, Saudi Arabia, and King Abdullah International Research Center, Jeddah, Saudi Arabia, 00966565733999, maghrabyha@ngha.med.sa

Dr. Almaghrabi is a Saudi assistant professor who received his fellowship from the Royal College of Physicians and Surgeons of Canada and Canadian Board of Anatomical Pathology (FRCPC). He served as a lecturer of pathology at King Saud bin Abdulaziz University for Health Science, Jeddah, Saudi Arabia. He is a program director of the anatomical pathology residency program at King Abdulaziz Medical City, Jeddah. Hatim has published 22 ISI/Scopus-indexed scientific papers. Hatim has special interest in cytopathology, liver, and kidney surgical pathology. ORCID: 0000-0002-0074-2245.

Mariana Fouad Gayyed

Department of Pathology, Faculty of Medicine, Minia University, Minia, Egypt, 00201001143941, mariana.gaid@mu.edu.eg

Prof. Gayyed is an Egyptian Professor of Pathology in the Faculty of Medicine, Minia University, Minia, Egypt. Mariana received her M.D. in pathology from the Department of Pathology in the Faculty of Medicine at Minia University. She served as a lecturer in the Department of Pathology at the Faculty of Medicine, University of Minia. She is also a pathology consultant at the National Cancer

Institute, Minia. Mariana has published 28 ISI/Scopus-indexed scientific papers with special research interests in breast pathology, gastrointestinal pathology, thyroid pathology, and molecular pathology. ORCID: 0000-0002-9455-2257.

Hanan Mohamed Abd Elmoneim

Department of Pathology, Faculty of Medicine, Umm Al-Qura University, Makkah, Saudi Arabia, and Department of Pathology, Faculty of Medicine, Minia University, Minia, Egypt, 00966594455902, hmnour@uqu.edu.sa

Prof. Abd Elmoneim is an Egyptian professor who received his Ph.D. in pathology from Glasgow Caledonian University, Scotland, United Kingdom. She served as lecturer and associate professor in the Department of Pathology in the Faculty of Medicine at the University of Minia, Egypt until 2011. In 2012, she was a professor of pathology and elected as head of the Department of Pathology in the Faculty of Medicine at Minia University. Currently, she is a professor of pathology in the Faculty of Medicine at Umm Al-Qura University, Makkah, Saudi Arabia and a pathology consultant at Umm Al-Qura University Medical Center. Hanan has published 35 ISI/Scopus-indexed scientific papers with special research interests in breast, urogenital, and molecular pathology. ORCID: 0000-0003-1715-5060.

References

Ålgars, A., Lintunen, M., Carpén, O., Ristamäki, R. and Sundström, J. (2011). EGFR gene copy number assessment from areas with highest EGFR expression predicts response to anti-EGFR therapy in colorectal cancer. *Br J. Cancer,* **105**(2), 255–62.

Aljuhani, W.S., Alanazi, A.M. and Alghafees, M.A. (2021). Primary bone sarcomas in KSA: A Saudi tumor registry review. *Journal of Taibah University Medical Sciences,* **16**(1), 77–85.

Basbous, M., Al-Jadiry, M., Belgaumi, A., Sultan, I., Al-Haddad, A., Jeha, S. and Saab, R. (2021). Childhood cancer care in the Middle East, North Africa, and West/Central Asia: A snapshot across five countries from the POEM network. *Cancer Epidemiol,* **71**(Pt B), 101727.

Birkman, E.M., Ålgars, A., Lintunen, M., Ristamäki, R., Sundström, J. and Carpén, O. (2016). EGFR gene amplification is relatively common and associates with outcome in intestinal adenocarcinoma of the stomach, gastro-oesophageal junction and distal oesophagus. *BMC Cancer,* **16**(1), 406–6.

Borgatti, A., Koopmeiners, J.S., Sarver, A.L., Winter, A.L., Stuebner, K., Todhunter, D., Rizzardi, A.E., Henriksen, J.C., Schmechel, S., Forster, C.L., Kim, J.-H., Froelich, J., Walz, J., Henson, M.S., Breen, M., Lindblad-Toh, K., Oh, F., Pilbeam, K., Modiano, J.F. and Vallera, D.A. (2017). Safe and effective sarcoma therapy through bispecific targeting of EGFR and uPAR. *Mol Cancer Ther,* **16**(5), 956–65.

Braun, A.C., de Mello, C.A.L., Corassa, M., Abdallah, E.A., Urvanegia, A.C., Alves, V.S., Flores, B., Díaz, M., Nicolau, U.R., Silva, V.S.E., Calsavara, V., Paterlini-Brechót, P. and Chinen, L.T.D. (2018). EGFR expression in circulating tumor cells from high-grade metastatic soft tissue sarcomas. *Cancer Biol Ther,* **19**(6), 454–60.

Capasso, M., Montella, A., Tirelli, M., Maiorino, T., Cantalupo, S. and Iolascon, A. (2020). Genetic predisposition to solid pediatric cancers. *Frontiers in Oncology,* **10**(n/a), 590033.

Choi, J.H. and Ro, J.Y. (2021). The 2020 WHO classification of tumors of soft tissue: Selected changes and new entities. *Adv Anat Pathol,* **28**(1), 44–58.

El Demellawy, D., McGowan-Jordan, J., de Nanassy, J., Chernetsova, E. and Nasr, A. (2017). Update on molecular findings in rhabdomyosarcoma. *Pathology,* **49**(3), 238–46.

Gaiser, T., Waha, A., Moessler, F., Bruckner, T., Pietsch, T. and von Deimling, A. (2009). Comparison of automated silver enhanced in situ hybridization and fluorescence in situ hybridization for evaluation of epidermal growth factor receptor status in human glioblastomas. *Modern Pathology,* **22**(9), 1263–71.

Ganti, R., Skapek, S.X., Zhang, J., Fuller, C.E., Wu, J., Billups, C.A., Breitfeld, P.P., Dalton, J.D., Meyer, W.H. and Khoury, J.D. (2006). Expression and genomic status of EGFR and ErbB-2 in alveolar and embryonal rhabdomyosarcoma. *Mod Pathol,* **19**(9), 1213–20.

Jagodzińska-Mucha, P., Raciborska, A., Koseła-Paterczyk, H., Kozak, K., Bilska, K., Świtaj, T., Falkowski, S., Dawidowska, A., Rutkowski, P. and Ługowska, I. (2021). Age as a prognostic factor in patients with ewing sarcoma-The Polish sarcoma group experience. *Journal of Clinical Medicine,* **10**(16), 3627.

Ji, X. L. and He, M. (2019). Sodium cantharidate targets STAT3 and abrogates EGFR inhibitor resistance in osteosarcoma. *Aging,* **11**(15), 5848–63.

Kager, L., Tamamyan, G. and Bielack, S. (2017). Novel insights and therapeutic interventions for pediatric osteosarcoma. *Future Oncol,* **13**(4), 357–68.

Kaufman, N.E.M., Dhingra, S., Jois, S.D. and Vicente, M.d.G.H. (2021). Molecular targeting of epidermal growth factor receptor (EGFR) and vascular endothelial growth factor receptor (VEGFR). *Molecules (Basel, Switzerland),* **26**(4), 1076.

Kersting, C., Packeisen, J., Leidinger, B., Brandt, B., von Wasielewski, R., Winkelmann, W., van Diest, P.J., Gosheger, G. and Buerger, H. (2006). Pitfalls in immunohistochemical assessment of EGFR expression in soft tissue sarcomas. *J Clin Pathol,* **59**(6), 585–90.

Kersting, N., Kunzler Souza, B., Araujo Vieira, I., Pereira Dos Santos, R., Brufatto Olguins, D., José Gregianin, L., Tesainer Brunetto, A., Lunardi Brunetto, A., Roesler, R., Brunetto de Farias, C. and Schwartsmann, G. (2018). Epidermal growth factor receptor regulation of ewing sarcoma cell function. *Oncology,* **94**(6), 383–93.

Martin-Giacalone, B.A., Weinstein, P.A., Plon, S.E. and Lupo, P.J. (2021). Pediatric rhabdomyosarcoma: Epidemiology and genetic susceptibility. *Journal of Clinical Medicine,* **10**(9), 2028. doi: 10.3390/jcm10092028.

Nadeem Abbas, M., Kausar, S., Wang, F., Zhao, Y. and Cui, H. (2019). Advances in targeting the epidermal growth factor receptor pathway by synthetic products and its regulation by epigenetic modulators as a therapy for glioblastoma. *Cells,* **8**(4), 350. DOI: 10.3390/cells8040350.

Oh, F., Todhunter, D., Taras, E., Vallera, D.A. and Borgatti, A. (2018). Targeting EGFR and uPAR on human rhabdomyosarcoma, osteosarcoma, and ovarian adenocarcinoma with a bispecific ligand-directed toxin. *Clin Pharmacol,* **10**(n/a), 113–21.

Oyama, T., Okamoto, K., Nakamura, R., Tajiri, R., Ikeda, H., Ninomiya, I. and Ooi, A. (2015). Overexpression and gene amplification of both ERBB2 and EGFR in an esophageal squamous cell carcinoma revealed by fluorescence in situ hybridization, multiplex ligation-dependent probe amplification and immunohistochemistry. *Pathology International,* **65**(11), 608–13.

Pilbeam, K., Wang, H., Taras, E., Bergerson, R.J., Ettestad, B., DeFor, T., Borgatti, A., Vallera, D.A. and Verneris, M.R. (2017). Targeting pediatric sarcoma with a bispecific ligand immunotoxin targeting urokinase and epidermal growth factor receptors. *Oncotarget,* **9**(15), 11938–47.

Roskoski, R., Jr. (2019). Small molecule inhibitors targeting the EGFR/ErbB family of protein-tyrosine kinases in human cancers. *Pharmacol Res,* **139**(n/a), 395–411.

Rot, S., Taubert, H., Bache, M., Greither, T., Würl, P., Holzhausen, H.-J., Eckert, A.W., Vordermark, D., and Kappler, M. (2018). Low HIF-1α and low EGFR mRNA expression significantly associate with poor survival in soft tissue sarcoma patients; the proteins react differently. *Int J Mol Sci,* **19**(12), 3842.

Rudzinski, E.R., Kelsey, A., Vokuhl, C., Linardic, C.M., Shipley, J., Hettmer, S., Koscielniak, E., Hawkins, D.S. and Bisogno, G. (2021). Pathology of childhood rhabdomyosarcoma: A consensus opinion document from the children's oncology group, European pediatric soft tissue sarcoma study group, and the cooperative weichteilsarkom studiengruppe. *Pediatr Blood Cancer,* **68**(3), e28798.

Salgado, C.M., Zin, A., Garrido, M., Kletskaya, I., DeVito, R., Reyes-Múgica, M., Bisogno, G., Donofrio, V. and Alaggio, R. (2020). Pediatric soft tissue tumors with BCOR ITD express EGFR but not OLIG2. *Pediatr Dev Pathol,* **23**(6), 424–30.

Sato, O., Wada, T., Kawai, A., Yamaguchi, U., Makimoto, A., Kokai, Y., Yamashita, T., Chuman, H., Beppu, Y., Tani, Y. and Hasegawa, T. (2005). Expression of epidermal growth factor receptor, ERBB2 and KIT in adult soft tissue sarcomas: a clinicopathologic study of 281 cases. *Cancer,* **103**(9), 1881–90.

Shi, Z., Chen, J., Guo, X., Cheng, L., Guo, X. and Yu, T. (2018). In silico identification of potent small molecule inhibitors targeting epidermal growth factor receptor 1. *J Cancer Res Ther,* **14**(1), 18–23.

Steliarova-Foucher, E., Colombet, M., Ries, L.A.G., Moreno, F., Dolya, A., Bray, F., Hesseling, P., Shin, H.Y. and Stiller, C.A. (2017). International incidence of childhood cancer, 2001-10: a population-based registry study. *The Lancet. Oncology,* **18**(6), 719–31.

Sunpaweravong, P., Sunpaweravong, S., Puttawibul, P., Mitarnun, W., Zeng, C., Barón, A.E., Franklin, W., Said, S. and Varella-Garcia, M. (2005). Epidermal growth factor receptor and cyclin D1 are independently amplified and overexpressed in esophageal squamous cell carcinoma. *J Cancer Res Clin Oncol,* **131**(2), 111–9.

Teng, H.W., Wang, H.W., Chen, W.M., Chao, T.C., Hsieh, Y.Y., Hsih, C.H., Tzeng, C.H., Chen, P.C. and Yen, C.C. (2011). Prevalence and prognostic influence of genomic changes of EGFR pathway markers in synovial sarcoma. *J Surg Oncol,* **103**(8), 773–81.

Thomas, R. and Weihua, Z. (2019). Rethink of EGFR in cancer with its kinase independent function on board. *Frontiers in oncology,* **9**(n/a), 800.

Wang, X., Yeo, R.X., Hogg, P.J., Goldstein, D., Crowe, P., Dilda, P.J. and Yang, J.-L. (2020). The synergistic inhibitory effect of combining therapies targeting EGFR and mitochondria in sarcomas. *Oncotarget,* **11**(1), 46–61.

Yang, J.-L., Gupta, R.D., Goldstein, D. and Crowe, P.J. (2017). Significance of phosphorylated epidermal growth factor receptor and its signal transducers in human soft tissue sarcoma. *Int J Mol Sci,* **18**(6), 1159.

Yang, J.L., Hannan, M.T., Russell, P.J. and Crowe, P.J. (2006). Expression of HER1/EGFR protein in human soft tissue sarcomas. *Eur J Surg Oncol,* **32**(4), 466–8.

Yang, M., Zhang, T., Zhang, Y., Ma, X., Han, J., Zeng, K., Jiang, Y., Wang, Z., Wang, Z., Xu, J., Hua, Y., Cai, Z. and Sun, W. (2021). MYLK4 promotes tumor progression through the activation of epidermal growth factor receptor signaling in osteosarcoma. *J Exp Clin Cancer Res,* **40**(1), 166.

Zöllner, S.K., Amatruda, J.F., Bauer, S., Collaud, S., de Álava, E., DuBois, S.G., Hardes, J., Hartmann, W., Kovar, H., Metzler, M., Shulman, D.S., Streitbürger, A., Timmermann, B., Toretsky, J.A., Uhlenbruch, Y., Vieth, V., Grünewald, T.G.P. and Dirksen, U. (2021). Ewing sarcoma- diagnosis, treatment, clinical challenges and future perspectives. *Journal of Clinical Medicine,* **10**(8), 1685.